



# EuroEcho2015 Imaging

19<sup>th</sup> Annual Meeting of the European Association of Cardiovascular Imaging, a registered branch of the ESC, in cooperation with the Spanish Working Group of Echocardiography.



## Congress-News

Saturday 5 December 2015

### The future of the European Association of Cardiovascular Imaging (EACVI)

By Professor Bogdan A. Popescu, European Association of Cardiovascular Imaging (EACVI) President-Elect

EACVI faces many opportunities and advantage should be taken of the new platform provided by the co-existence of all the imaging modalities. A great opportunity is given by the increased number of EACVI members – currently more than 5,000 of which approximately one third is younger than 35 years. Younger colleagues should be supported as much as possible as they represent the future and are the most dynamic group within the EACVI.

#### Education is key

Proper education should be provided throughout Europe in all the imaging modalities and EACVI needs to find ways to reach people who cannot easily attend congresses/courses, mainly for financial reasons such as Eastern European countries. Education and certification need to be provided too, not only on the use of high-end machines but also taking into consideration the very dynamic field of pocket-size imaging devices.

#### Role of research

Research-wise many important clinical questions need to be addressed and the incremental role of imaging in terms of patient management and outcomes demonstrated. The Research and Innovation committee within the EACVI will address this need in a multi-disciplinary fashion. This is definitely a very important mission of the EACVI for the cardiovascular community. Apart from issu-

ing its own recommendation papers about the use of imaging in different settings, the EACVI needs to provide evidence for the role of imaging in different diagnostic and treatment algorithms within the ESC Guidelines of medical practice.

#### EuroEcho-Imaging: the world's largest cardiovascular imaging congress

EuroEcho Imaging has gradually expanded its scope from echocardiography-only to the incorporation of other imaging modalities such as CMR or CT/Nuclear and has become much more clinically-oriented. This trend will continue as we aim for a broad forum to discuss with colleagues from many different specialties the role and use of imaging for proper clinical management.

#### Future perspectives

I am confident about the future of the EACVI. We are fortunate to have in the EACVI team great people, not only professionally but also from a personal perspective. The collaboration with and the feedback from the National Societies are extremely important as we should continuously adapt our plans and projects to the needs of our members. The EACVI relies and will rely heavily on its three sections: echocardiography, CMR, and Nuclear & Cardiac CT as the main pillars of its foundation. Apart from all the Board and committees members EACVI also relies very much on the support from the ESC and the Heart House staff. Therefore, it is certain that important things can



Professor Bogdan A. Popescu, EACVI President-Elect, Bucharest, Romania

be done together and hopefully, this may ultimately lead to a better patient management.

Bogdan Alexandru Popescu is Associate Professor of cardiology at the University of Medicine and Pharmacy 'Carol Davila' in Bucharest, Romania. He is Director of Euroecolab, the European accredited echocardiography laboratory at the Institute of Cardiovascular Diseases in Bucharest (the largest cardiovascular institution in Romania), and has published more than 100 full-text original articles in peer-reviewed journals. Professor Popescu served as a member of the Committee for Practice Guidelines of the ESC (2008-2012). He is President-Elect of the European Association of Cardiovascular Imaging - EACVI (2014-2016) as well as Vice-President of the Romanian Society of Cardiology (2014-2017).

Download the 2015 EuroEcho-Imaging Mobile App



#### Today in this issue ...

Imaging for the diagnosis of Coronary Artery Disease (CAD) - what is new? **Page 2**

Professor Fausto Pinto, ESC President; a varied career in cardiology **Page 3**

EACVI Adult TTE certification exam in Spanish – how will this help the Community? **Page 4**

Imaging in Congenital Heart Disease **Page 4**

#### What's new in imaging for CAD diagnosis by Professor Neglia

Functional and anatomical CVI are an essential component in the management of patients with cardiovascular conditions. The need for CVI will increase and CVI techniques are evolving rapidly in terms of performance and diversity; new developments in cardiovascular imaging applied to the diagnosis of CAD are very promising. **Page 2**

## Don't Miss

- ▶ 10.00-11.00 Case based session: "See that case at least once", Agora
- ▶ 11.00-12.30 EuroEcho 2015 highlights sessions, Room Florence

Follow us at  
**#euroecho**  
on Twitter

## Imaging for the diagnosis of Coronary Artery Disease (CAD) – what is new?


Cardiovascular imaging (CVI) is evolving rapidly, placing new demands on the cardiologists' profession and on health-care systems. Functional and anatomical CVI is more and more an essential component in the management of patients with cardiovascular conditions. It is thus likely that the need for CVI will continue to increase over the coming years due to the changes in CV diseases epidemiology and ageing of the population. In addition, CVI techniques are evolving rapidly in terms of performance and diversity. The availability of more advanced imaging technology combined with an expanded target population would thus require new professional skills for properly indicate, acquire, interpret and use imaging information in the diagnostic and therapeutic decision making process of the single patient. Whether this would be better achieved by integration of different specialists (clinical cardiologists, cardiac imaging experts, interventional cardiologists) in 'heart teams' or by expanding the competences of single professionals is an opened discussion.

### Approaches for CAD

Among CV diseases, coronary artery disease (CAD) is the single most common cause of health-related death in the EU, accounting for at least 681,000 deaths each year and costing the EU economy almost 38 billion Euro a year. Early diagnosis, invasive coronary procedures and effective medical treatments led to a significant decrease in mortality due to acute coronary syndromes. In patients with stable CAD, however, the effectiveness of diagnostic and therapeutic management of patients on outcome is more questionable. There is increasing awareness that invasive coronary angiography (ICA) is used too frequently as an early diagnostic testing in these patients, providing negative findings in up to 40% of exams and often driving inappropriate revascularization procedures without clear effects on symptoms and prognosis. Significant improvements in non-invasive imaging have driven increased interest to use these procedures more routinely in the diagnostic algorithm for patients with suspected CAD to reduce costs and risks and to better address personalized management.

### Choices to be made

In the current clinical setting, however, there is no clear guide on which non-invasive imaging approach is most effective in the specific patient so that the choice is mostly conditioned by availability, costs, local



Professor Danilo Neglia, EACVI Nuclear Cardiology/Cardiac Computed Tomography Section Chair, Pisa, Italy

preferences and expertise. Non-invasive testing provides different, and often not superimposable, information. Cardiac computed tomography angiography (CCTA) is used for non-invasively assessing the presence and the severity of 'anatomical' CAD. The functional relevance of the disease can be assessed by stress imaging evaluating myocardial perfusion (SPECT, PET, CMR), myocardial/coronary flow reserve (SPECT/PET/DopplerECHO) or wall motion (ECHO, CMR). According to current European Guidelines in Stable CAD, what would be required in each patient is the definition of both the presence of an anatomical coronary disease and of its functional effects on the myocardium to indicate revascularization. Nevertheless, non-invasive anatomical and functional evaluation is rarely used in the same patient delegating to the invasive study the final assessment.

### Comparative studies

A few studies have compared different non-invasive imaging strategies for their ability to recognize patients with functionally significant CAD and to correctly address treatment in real world practice. Of note EVINCI is the most recent European multicenter study in which both anatomical imaging by CCTA and functional imaging (chosen among all available stress imaging modalities) were performed in the same patient with suspected CAD before ICA. The study demonstrated a higher accuracy of CCTA as compared with stress imaging in recognizing patients with significant disease demonstrated at invasive assessment. It also showed that the prevalence of significant CAD was lower than expected (29%) in a current European population clinically selected for diagnostic screening. Moreover, it evidenced that stress imaging is often per-

formed using suboptimal protocols. These could be relevant factors explaining the better performance of CCTA in this population. The clinical follow-up of the EVINCI population was completed in September 2015 and results on the impact on outcome of different non-invasive imaging strategies are expected soon. In fact, this would be the most clinically valuable end-point of comparative effectiveness studies on imaging in CAD.

The PROMISE study is the most recent trial which was designed to compare the clinical effectiveness of initial functional testing to a strategy of initial anatomic imaging with CCTA in symptomatic patients with suspected CAD. It failed to demonstrate prognostic benefits of either of the two strategies. This trial confirmed that not only the prevalence of disease but also the long term clinical risk is lower than expected in the population currently submitted to diagnostic screening for suspected CAD.

### Costs play a role

All this considered, an important additional dimension to define the appropriate use of imaging in patients with suspected stable CAD would be the relationship between clinical benefits, procedural risks and costs.

An ideal comparative cost-effectiveness analysis should include the risks associated with radiation exposure, magnetic fields, stress protocols, over-diagnosis or missed diagnosis, related direct and indirect costs with outcome as an end-point.

Despite some relevant available studies such as the CE-MARC which addressed the cost-effectiveness of combined strategies including CMR, such a comprehensive health eco-

nomie assessment of multi-modality imaging in CAD is still lacking.

### Future perspectives

New developments in cardiovascular imaging applied to the diagnosis of CAD are very promising. One possibility to get integrated information on coronary anatomy and function is allowed by fusion or hybrid imaging obtained by CCTA and SPECT/PET (with possible absolute quantification of flow), with an ultralow radiation exposure. Developments in CMR would allow a similar approach with a single modality. Use of stress ECHO for combined assessment of wall motion and coronary flow reserve already demonstrated improved performance. Great interest has been recently risen by perfusion and FFR measurements by CT and we will wait for the results of the large on-going PROSPECT and CRE-DENCE studies.

A new frontier would be to better select patients even before non-invasive imaging. Increasing evidence suggests that the accepted clinical definition of pre-test probability of CAD before imaging is overestimated in the actual European population. Based on the EVINCI study data it was recently demonstrated that simple predictive models including clinical variables and a few biomarkers could be able to reclassify pre-test probability from intermediate to low in 56% of patients with suspected CAD thus potentially avoiding useless and costly diagnostic tests. While waiting for new comparative research studies and for the implementation of technical developments in clinical practice, the assessment of the current status of the use of CV imaging in Europe has become a priority for the Imaging Taskforce of European Association of Cardiovascular Imaging (EACVI) and the European Society of Cardiology (ESC). A recent report highlighted the lack of national and international CV imaging registries, which could highlight the current use, effectiveness, costs and impact on outcome of non invasive imaging in patients with stable CAD in Europe.

*Professor Danilo Neglia was educated at the Università di Pisa where he studied medicine and specialized in cardiology. He obtained his PhD in 1984 at the Scuola Superiore 'Sant' Anna' and specialized in Nuclear Medicine in 1987. He is Senior Cardiologist at Fondazione Toscana G. Monasterio, Associate Researcher at CNR Institute of Clinical Physiology and Affiliate Professor at Scuola Superiore Sant'Anna in Pisa, Italy.*



## Professor Fausto Pinto, ESC President; a varied career in cardiology

The current President of the European Society of Cardiology (ESC), Professor Fausto J. Pinto, MD, PhD, FESC, FACC, FSCAI, FASE stood at the basis of shaping echocardiography as he was the founder (and President) of the European Association of Echocardiography (2002-04), which is a registered branch of the ESC. He was the chairman of the CPC (Congress Program Committee) of the ESC (2008-10), then became Vice President (2010-12) followed by President-Elect of ESC (2012-14) and is currently the President of the European Society of Cardiology until 2016.

### Background

His remarkable medical career started to take shape when he graduated from Lisbon University Medical School in 1984 and subsequently continued his medical education by fulfilling his cardiology internship at Santa Maria University Hospital - CHLN, E.P.E. in Lisbon, Portugal between 1987 and 1989 and Stanford University Medical School (CA, USA) between 1990 and 1991. He started there as a Research Fellow and became a Clinical Attending in the Echocardiography laboratory in 1991 up until 1993. He was also awarded with an Interventional Cardiology Fellowship at the same institution. From 1992 to 1993 he held an Interventional Cardiology Fellowship there and went on to complete his PhD at Lisbon University Medical



Professor Fausto J. Pinto

School in Lisbon in Portugal. Up until today, Professor Pinto keeps his educational levels up to scratch, having completed the Good Clinical Practice, EU GCP Directives (2001/20 & 2005/28) Whitehall Training in 2014.

### Honors and awards

Professor Pinto has acquired a magnitude of honors and awards over the years, amongst which are a Honorary Diploma by the Russian Society of Cardiology (Moscow, 2015), Doctor Honoris Causa of the Semmelweis University in Budapest (Hungary, 2015), Lettura Magistrale at the ANMCO Congress: "Feeding the Planet. Energy for Life", Milan (Italy, 2015), the Medal of Honor of the Bulgarian Society of Cardiology (2014)

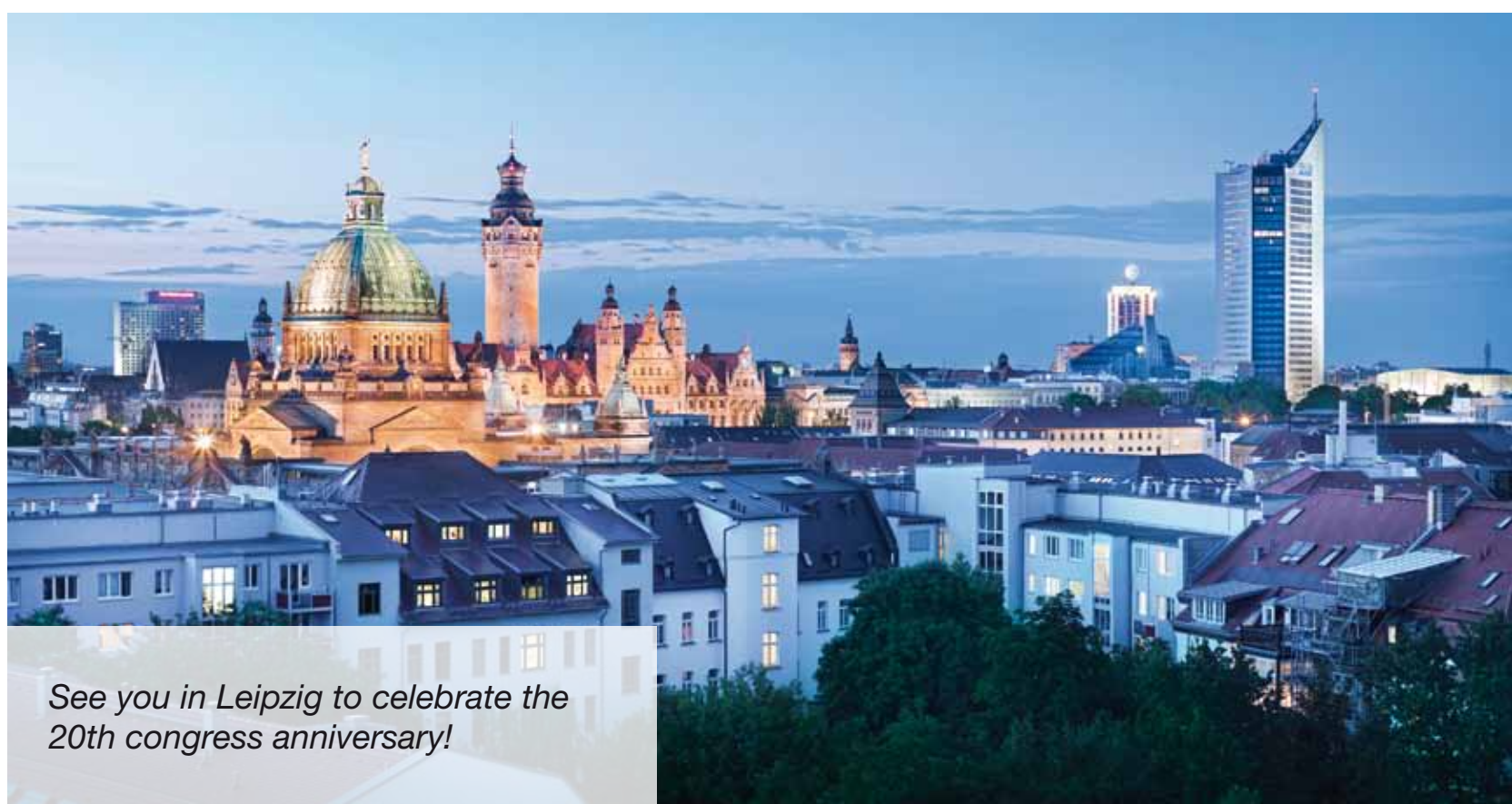and the Medal of Honor of the Cuban Society of Cardiology (2014). He is honorary member of more than 20 scientific societies and Academies.

### Current activities

His current activities are many; he is Dean of the Faculty of Medicine, University of Lisbon, Head of the Cardiology Department of Santa Maria University Hospital, CHLN, E.P.E., Full Professor of Medicine/Cardiology at Lisbon University Medical School, Chair of the Cardiology Clinic at Lisbon University Medical School and Scientific Coordinator of the Cardiovascular Centre of the University of Lisbon (CCUL), President of the Association for Research and Development of the Faculty of Medi-

cine (AIDFM), Director of the Lisbon Cardiovascular Institute (ICVL) and he performs postgraduate supervision (MSc, PhD, Postdocs) at Lisbon University Medical School, Imperial College London, Escola Nacional de Saúde Pública / National School of Public Health (among others). Besides, Professor Pinto is involved in many cardiological and echocardiographic societies, being a fellow of the European Society of Cardiology (FESC), the American College of Cardiology (FACC), the American Society of Angiology (FASA), the Society for Cardiac Angiography and Interventions (FSCAI) and the American Society of Echocardiography (FASE). He is also Editor in Chief of the Portuguese Journal of Cardiology (1999-2015), member of the Editorial of Board of several international peer-reviewed journals and is an Expert Reviewer for the European Commission.

*Professor Pinto participated in many funded research projects either as principal investigator, co-investigator, national as well as international. His research interests are advanced Cardiovascular Imaging, Intracoronary Ultrasound, Echocardiography, Heart failure, Diastology and Hypertension. Professor Pinto has published over 300 papers and has presented over 1300 lectures/chairmanships at national and mostly international meetings.*



See you in Leipzig to celebrate the 20th congress anniversary!



## EACVI Adult TTE certification exam in Spanish – how will this help the Community?

**Professor Leopoldo Perez de Isla, Elected Leader of the Spanish Echocardiography Working Group**

"I think the EACVI Adult Transthoracic Echocardiography (TTE) certification exam in Spanish provides an unique opportunity for a lot of Spanish-speaking cardiologists and sonographers. As a matter of fact, Spanish language is the third most used language in the world. As you can imagine, when you are preparing to do an examination, you always prefer it to be in your mother tongue in order to avoid unnecessary stress which is why this is such a great initiative. Dr. José Juan Gómez de Diego and myself - in co-ordination with dr. Alexander Stefanidis and all the members of the EACVI Transthoracic Echocardiography accreditation team – were directly involved in the translation and optimization of the exam. This is actually the first time that this experience as I would call it, is carried out. And it is not only people from Spain but also from Latin America, except of course Brazil where Portuguese is the main language, who may be able to join this exam. Having the Transthoracic Echocardiography certification exam in Spanish will help clinicians and physicians by avoiding unnecessary stress during



Professor Leopoldo Perez de Isla

the exam as a result of the use of a language which is not one's native tongue. This is an important issue as it may (negatively) influence the results, not so much because the knowledge is not up to scratch but due to misunderstanding and misinterpretation of questions. As such, the exam results would not reflect the quality and knowledge level of the person taking the exam but pose an unnecessary language barrier. For patients, the availability of the TTE certification exam in Spanish means that they do not lose the opportunity to be managed by an accredited expert if their doctor does not speak English sufficiently. Personally, I hope that – as such an important language worldwide – Spanish should be offered in following exams too."

## Imaging in Congenital Heart Disease

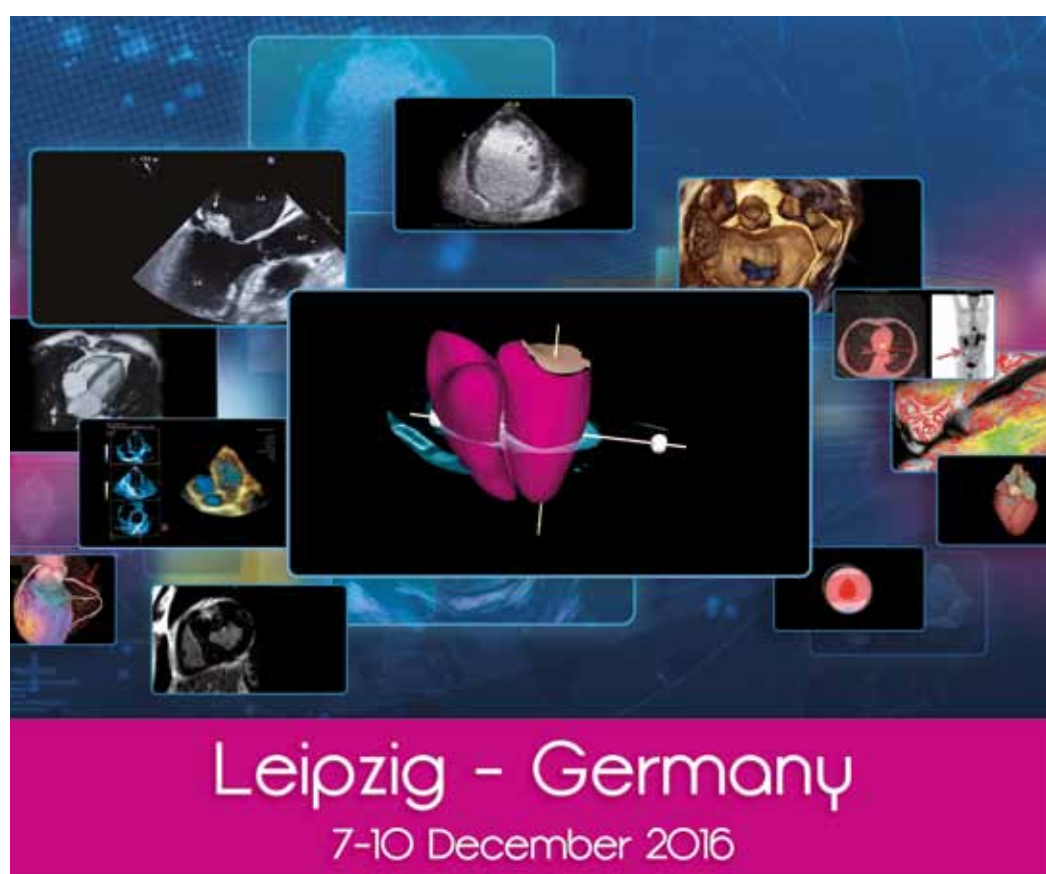**Professor Owen Miller, EACVI Board member, Consultant in Paediatric and Fetal Cardiology, Evelina London Children's Hospital, UK**



Professor Owen Miller

"The first investigation in children with suspected CHD is always imaging; you need to clarify the underlying anatomy and cardiac connections, assess whether there are normal chambers and valves present and so on. Even before birth, fetal echocardiography is now standard and more recently, fetal cardiac MRI is being used to look at structures in the fetal heart. After birth, if the clinical exam suggests a heart problem, echocardiography is the primary modality for a comprehensive examination of the heart of a newborn. Some children have very complex abnormalities and more investigation is needed; multi-modality investigations to understand the 3-dimensional structure of the heart and vessels include MRI and CT, often all three combined in particularly complex lesions. Once a child is diagnosed with CHD, cardiac surgery might be needed. Pre-operative, intra-operative and post-operative echocardiography is now standard of care, often without any need for angiography, thus sparing the child from further radiation exposure. Finally, post-operative follow-up of CHD patients – spanning over dec-

ades – also requires a repeatable and low-risk modality where echocardiography again proves to be ideal. This is of particular importance in the growing child where surgery which may have been performed as a newborn might be repeated in subsequent years. Adults with CHD (ACHD) need specific care in terms of on-going progress assessments and monitoring where echocardiography will continue to play a role as well as a higher demand for CT and MRI. Assessing heart function again becomes more important as the diagnosis is already known. Now that paediatric cardiology is firmly established and growing, we as pediatric cardiologists would like to be more involved in the development of new technology. A dialogue on CHD between clinicians and industry is what we are looking for."



**EuroEcho  
Imaging 2016**  
EDITION

28th Annual Meeting of the European Association of Cardiovascular Imaging, a registered branch of the ESC, in cooperation with the German Working Group of Echocardiography

www.escardio.org/EACVI



**2016 Main themes:  
arrhythmias &  
valve diseases**